

phenytoin were given. In addition to saline bolus, noradrenaline infusion for hypotension was started and carefully titrated. Blood gas analysis showed respiratory and metabolic acidosis. The hemogram on admission showed hemoglobin 9.5 g/dL, platelet count  $173 \times 10^9/L$ ; and total leucocyte counts  $7.2 \times 10^9/L$  (neutrophils, 76.7%). Liver function tests and renal function tests, coagulation profile and blood glucose were normal. C-reactive protein (CRP) was elevated 36.4 mg/L. Chest X-ray showed left upper lobe collapse and bilateral opacities. The National poison information centre was consulted and supportive management was advised as there was no specific antidote. Her urine output remained normal.

Patient started having high grade fever after 24 hours. Repeat investigations showed leucocytosis of  $13.5 \times 10^9/L$  (neutrophils 83%) and CRP of 67.8 mg/L. Blood culture and endotracheal secretions for culture showed no growth. In view of shock and hypotension, echocardiography was done, which showed normal left ventricular ejection fraction of 65%. Gradually, sensorium improved in the form of intermittent awakening after 48 hours, and GCS became 13/15 by day five. Patient became afebrile after four days. Hemodynamic improvement started only after day three, and vasopressors were slowly tapered off. Ventilatory requirements which were high initially, also decreased from day three and in view of neurological and hemodynamic stability, child was weaned off from ventilator on day five and extubated. Repeat hemogram, CRP and Chest X-ray became normal by eighth day. Neuroimaging could not be done initially as the child was critical, and was refused later by parents in view of clinical improvement. She was discharged after nine days of hospitalization in a stable condition on oral clindamycin (total duration of 14 days).

Ivermectin, in standard therapeutic doses, has both excellent parasitocidal efficacy and high tolerability [1]. Ivermectin does not readily cross the blood-brain barrier (BBB) in humans as it is effluxed by ATP-binding cassette subfamily B member 1 (ABCB1) transporter also called P-glycoprotein drug pump or *mdr-1* located in the blood/brain barrier [1,3]. Hence, neurological adverse reactions are rare unless there is overdosage [1]. Our patient ingested 30 mg/kg of ivermectin, which was

almost 100 times the recommended dose. Usually, a single oral dose of 150 to 300 mcg/kg is recommended, and 200 mcg/kg in scabies [4,5]. We suspected ivermectin poisoning due to the history, since encephalopathy and coma are well-documented side effects of ivermectin treatment in animals, and after ruling out other usual causes of coma. Severe neurological toxicities have been reported in public health programs in Africa, possibly due to concomitant infestations with high densities of *loa loa*, genetic predisposition, and co-infestations [1,6]. Additional intake of drugs that inhibit CYP3A4 and polymorphisms in the *mdr-1* gene could also result in toxicity [1]. A recent case report of ivermectin taken in recommended dose, by a 13-year-old child, attributed the resulting neuro-toxicity, to human *ABCB1* nonsense mutations, which had led to loss of the neurological protective *ABCB1* activity [3].

In our patient, despite there being no specific antidote, vigorous monitoring, and supportive critical care treatment proved to be lifesaving.

**Neetu Talwar,\* Niti Tripathi, Krishan Chugh**

*Division of Pediatric Pulmonology, Fortis Memorial Research Institute, Sector 44, Gurugram, Haryana.*

*\*neetu.talwar1306@gmail.com*

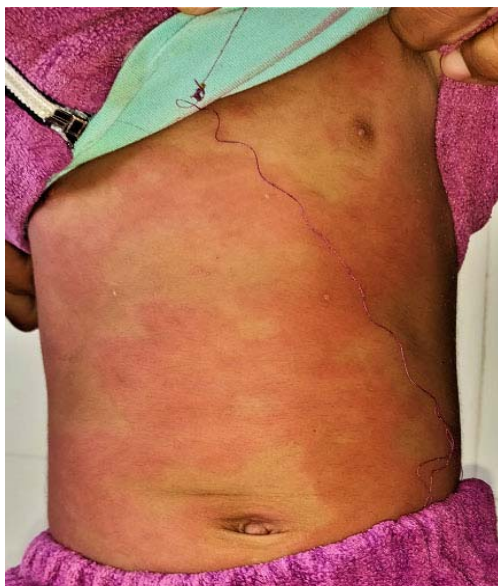## REFERENCES

1. Chandler RE. Serious neurological adverse events after ivermectin-Do they occur beyond the indication of onchocerciasis? *Am J Trop Med Hyg.* 2018;98:382-88.
2. Caly L, Druce JD, Catton MG, et al. The FDA-approved drug ivermectin inhibits the replication of SARS-CoV-2 in vitro. *Antiviral Res.* 2020;178:104787.
3. Baudou E, Lespine A, Durrieu G, et al. Serious ivermectin toxicity and human *ABCB1* nonsense mutations. *N Engl J Med.* 2020; 383:787-89.
4. Jans DA, Wagstaff KM. The broad spectrum host-directed agent ivermectin as an antiviral for SARS-CoV-2 ? *Biochem Biophys Res Commun.* 2021;538:163-72.
5. González Canga A, Sahagún Prieto AM, Díez Liébana MJ, et al. The pharmacokinetics and interactions of ivermectin in humans—A mini-review. *AAPS J.* 2008;10:42-6.
6. Boussinesq M, Gardon J, Gardon-Wendel N, Chippaux JP. Clinical picture, epidemiology and outcome of Loa-associated serious adverse events related to mass ivermectin treatment of onchocerciasis in Cameroon. *Filaria J.* 2003;2:S4.

## Multisystem Inflammatory Syndrome in Children Related to COVID-19 With Urticarial Vasculitis – A Double Whammy!

There is still a dearth of data of the involvement of skin in the coronavirus disease 2019 (COVID-19), especially in pediatric patients. Herein, we describe the report of a child with COVID-19 related multisystem inflammatory syndrome in children (MIS-C), who developed hypocomplementemic urticarial vasculitis syndrome (HUVS) after recovery.

A previously healthy 18-month-old boy with a five day history of fever and abdominal tenderness was admitted to the pediatric in-patient department. His mother was suffering from COVID-19. On mucocutaneous examination, the child had multiple annular polycyclic erythematous plaques on trunk with conjunctival erythema (**Fig. 1**). The lesions had been rapidly progressive and persistent for the last three days. The child was febrile (39.4°C) and hypoxemic. The child was also experiencing diarrhea for three days along with hypotension (blood pressure 90/60 mmHg). Laboratory investigations revealed a positive RT-PCR for SARS-CoV-2 on two tests done three days apart, along with metabolic acidosis, leukocytosis, neutrophilia, lymphopenia, anemia and hypoalbuminemia with albuminuria.

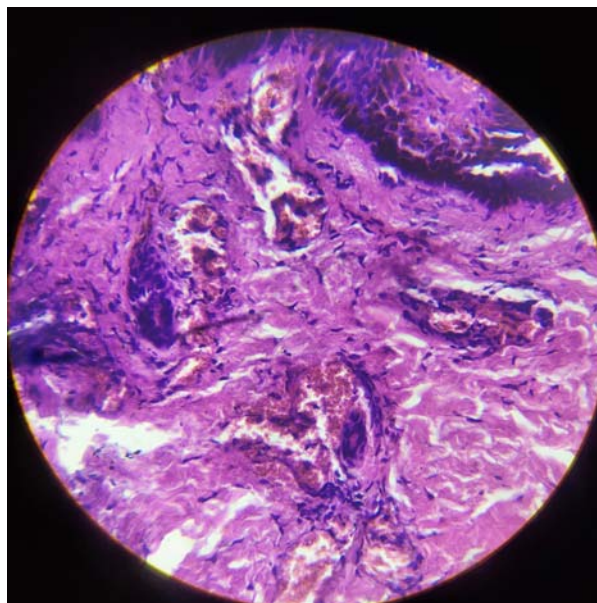


**Fig. 1** Multiple annular polycyclic erythematous urticarial plaques on trunk.

Erythrocyte sedimentation rate (21 mm first hour reading) and C-reactive protein (19 mg/dL) were raised.

High resolution computed tomography (HRCT) showed ground glass opacities in <20% of both lungs. A diagnosis of MIS-C was made. Intravenous steroids and blood transfusion were given and ceftriaxone was administered, along with oxygen. Fever and other manifestations subsided in 14 days. However, the urticarial rash kept recurring even after 6 weeks on-and-off treatment with antihistaminics, raising the suspicion of chronic urticaria. Investigations to rule out possible causes of chronic urticaria revealed low complement levels, viz., C3 (30 mg/dL), C4 (6 mg/dL), CH50 (13 U/mL) and C1q (4.1 mg/dL), and persistent hypoalbuminemia. Histopathological analysis demonstrated superficial and deep perivascular and interstitial infiltrates, small blood vessel wall degeneration and a leukocytoclasia (**Fig. 2**).

Significant family history compatible with autoimmune diseases included a maternal grandmother with vitiligo and bullous pemphigoid, as well as hypothyroidism in mother. The child was diagnosed with hypocomplementemic urticarial vasculitis syndrome (HUVS). The child has been prescribed oral hydroxyzine hydrochloride and 4 mg monteleukast daily. Although, the child still develops flares, they are relieved on a temporary basis by a short course of oral steroids.



**Fig. 2** On histopathological analysis presence of superficial and deep perivascular and interstitial infiltrates, small blood vessel wall degeneration and a leukocytoclasia (H and E, 400x).

It has been established that COVID-19 infection can cause delayed hypersensitivity reaction, which can trigger MIS-C and vasculitis in recovering patients [1-3]. We hypothesize that the viral infection can potentially trigger complement deficiency and urticarial vasculitis, as seen in our case. Although our patient is currently not exhibiting any signs of an extracutaneous involvement, his presentation requires close monitoring. Clinicians need to be aware of COVID-19 as a potential cause for such presentation in children.

**ALPANA MOHTA,\* RAJESH DUTT MEHTA,  
BHIKAM CHAND GHIYA**

*Department of Dermatology, Venereology and Leprosy,  
Sardar Patel Medical College,  
Bikaner, Rajasthan.*

*\*dralpanamohta10@gmail.com*

## REFERENCES

1. Becker RC. COVID-19-associated vasculitis and vasculopathy. *J Thromb Thrombolysis*. 2020;50:499-511.
2. Camprodon Gómez M, González-Cruz C, Ferrer B, Barberá MJ. Leucocytoclastic vasculitis in a patient with COVID-19 with positive SARS-CoV-2 PCR in skin biopsy. *BMJ Case Rep*. 2020;13:e238039.
3. Jain S, Sen S, Lakshmivenkateshiah S, Bobhate P, et al. Multi-system inflammatory syndrome in children with COVID-19 in Mumbai, India. *Indian Pediatr*. 2020;57:1015-9.