

Ochoa or Urofacial Syndrome

NR SUTAY, RAJESH KULKARNI AND MANISH K ARYA

From the Department of Pediatrics, Grant Medical College and Sir J.J. Group of Hospitals, Byculla, Mumbai 400 008, India.

Correspondence to: Dr Manish K Arya, Department of Pediatrics, Grant Medical College and Sir J.J. Group of Hospitals, Byculla, Mumbai 400 008, India.
manjioo7@yahoo.co.in

Received: September 25, 2008;

Initial review: October 8, 2008;

Accepted: April 15, 2009.

We report a 10 year old boy presenting with bilateral hydronephrosis and peculiar facial expression suggestive of Ochoa Syndrome or Urofacial syndrome. He had chronic renal failure which was managed conservatively.

Key words: Obstructive Uropathy, Ochoa Syndrome, Urofacial Syndrome.

Ochoa or Urofacial syndrome is a rare syndrome with over 100 cases reported world over(1). It is an autosomal recessive condition characterised by hydronephrosis with peculiar facial expression due to abnormal nerve signals between bladder and spinal cord. Here we report the first case of this syndrome from India.

CASE REPORT

A 10 year old boy was admitted for fever and tachypnea for 10 days. The patient had no other respiratory or cardiac complaints. On examination, he had tachycardia and tachypnoea with acidotic breathing, the blood pressure was 142/96 mm Hg in the right arm supine position. The patient was wasted, stunted and showed severe pallor with signs of vitamins A and vitamin B deficiency. There was a peculiar facial expression characterised by inverted facial smile with no facial asymmetry (*Fig. 1*). There was history of similar facial expression in maternal grandfather. There were no other systemic findings. The haemoglobin level was 5.8 g/dL, peripheral smear showed normochromic normocytic anemia. The blood pH was 7.16, bicarbonate 5.1 mEq/l/L, blood urea 136 mg/dL and creatinine 3.5 mg/dL; Ultrasonography of abdomen showed bilateral

moderate hydronephrosis with hydroureter and thickened and trabeculated bladder wall, suggestive of obstructive uropathy. A micturating cystourethrogram showed features suggestive of neurogenic bladder. Urodyna-mic study showed urge incontinence, hypocontractile detrusor with post void residual urine and reduced maximum and average flow rates suggestive of neurogenic bladder. DMSA and DTPA study showed bilateral impaired cortical function with significantly delayed excretion from both the kidneys. MRI brain and spine was within normal limit. Patient was managed for chronic renal failure and subsequently treated with clean intermittent catheterization (CIC), antibiotic prophylaxis and anticholinergic therapy.

DISCUSSION

Ochoa or Urofacial Syndrome is characterized by an abnormal facial expression and obstructive disease of the urinary tract that are present at birth(2). It occurs due to disruption (loss of functional genes) or mutations of a gene on 10q23-q24(3). Patient may develop renal failure in adolescence. The urinary abnormality is an obstructive uropathy in which failure of nerve signals between the bladder and the spinal cord results in incomplete emptying of the bladder(3). In addition, neurogenic bladder may

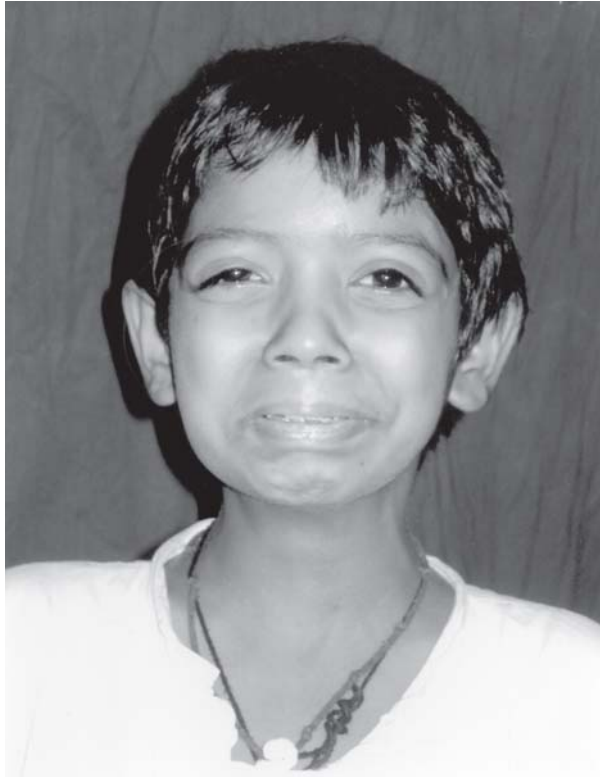


FIG.1 Ochoa Syndrome.

result in incontnence, urinary tract infections, and/or hydronephrosis. Patients show a peculiar facial expression; on smiling their facial musculature turns upside down or "inverts" so that they appear to be grimacing or crying(3). Some patients have unilateral facial palsy and two thirds have moderate to severe

constipation(4). Cryptorchidism may be an associated finding.

To map the UFS gene, a genome screen using a combination of homozygosity-mapping and DNA-pooling strategies are required. The management includes appropriate medical treatment for chronic renal failure and urinary tract infection and management for obstructive uropathy.

Contributors: MKA and RK drafted the manuscript and searched the literature. MKA and NRS contributed to patient management. MKA will act as guarantor.

Funding: None.

Competing interests: None stated.

REFERENCES

1. Ochoa B. Can a congenital dysfunctional bladder be diagnosed from a smile? The Ochoa syndrome updated. *Pediatr Nephrol* 2004; 19: 6-12.
2. Ochoa B, Walker RD, She JX. Homozygosity and linkage- disequilibrium mapping of the urofacial (Ochoa) syndrome gene to a 1-cM interval on chromosome 10q23-q24. *Am J Human Genet* 1997; 60: 1461-1467.
3. Urofacial Syndrome. National Organization for Rare Disorders(Online). Available from URL <http://www.rarediseases.org/search/rdblist.html>. Accessed March 31, 2009.
4. Ochoa B, Gorlin R, Opitz J. Urofacial (Ochoa) syndrome. *Am J Med Genet* 1987; 27: 661-667.