

## Sirenomelia Sequence

S. Chandran  
L. Krishnan  
G.G. Christo

Sirenomelia, also known as symphodia, is a rare lethal anomaly with a frequency of one in 60,000 live births. Known since antiquity, it has always been considered a severe form of the caudal regression syndrome (CRS). Resurgence of interest in this condition has occurred because new evidence shows that it is unrelated in etiology to CRS(1). Over the last 15 years only six Indian reports have appeared describing this condition(2-7).

### Case Report

The infant was born to a 21-year-old primigrada, married to a first degree relative. The antenatal period was uneventful till the eighth month of gestation, when on routine examination the patient was noticed to have a markedly reduced uterine size. She had also lost three kilos since the previous antenatal checkup a month before. There were no fetal heart sounds and she spontaneously expelled the fetus the following day.

On examination, the macerated still-

born weighed 1450 g. The skull was a mass of floating bones. Potter facies was not evident. The rectum was absent. External genitalia consisted of a small protruberance with no orifices. There was a single fused lower limb with a midline raphe, and only one foot with normal toes. Only one umbilical artery was present.

X-ray of the lower limb showed soft tissue fusion but separate femurs and tibiae. The right fibula was displaced medially. There was only one set of foot bones. No vertebral anomalies were noted (Fig. 1). Postmortem was refused.

### Discussion

Sirenomelia, until quite recently, has been considered to be a severe form of caudal regression syndrome(1). CRS is the consequence of a wedge shaped early deficit of the posterior axis caudal blastema allowing for the fusion of early limb buds and absence or incomplete development of the intervening caudal structures. This theory does not accommodate the consistent presence of a large vitelline vessel arising high in the abdomen or satisfactorily explain the spectrum of defects that occur.

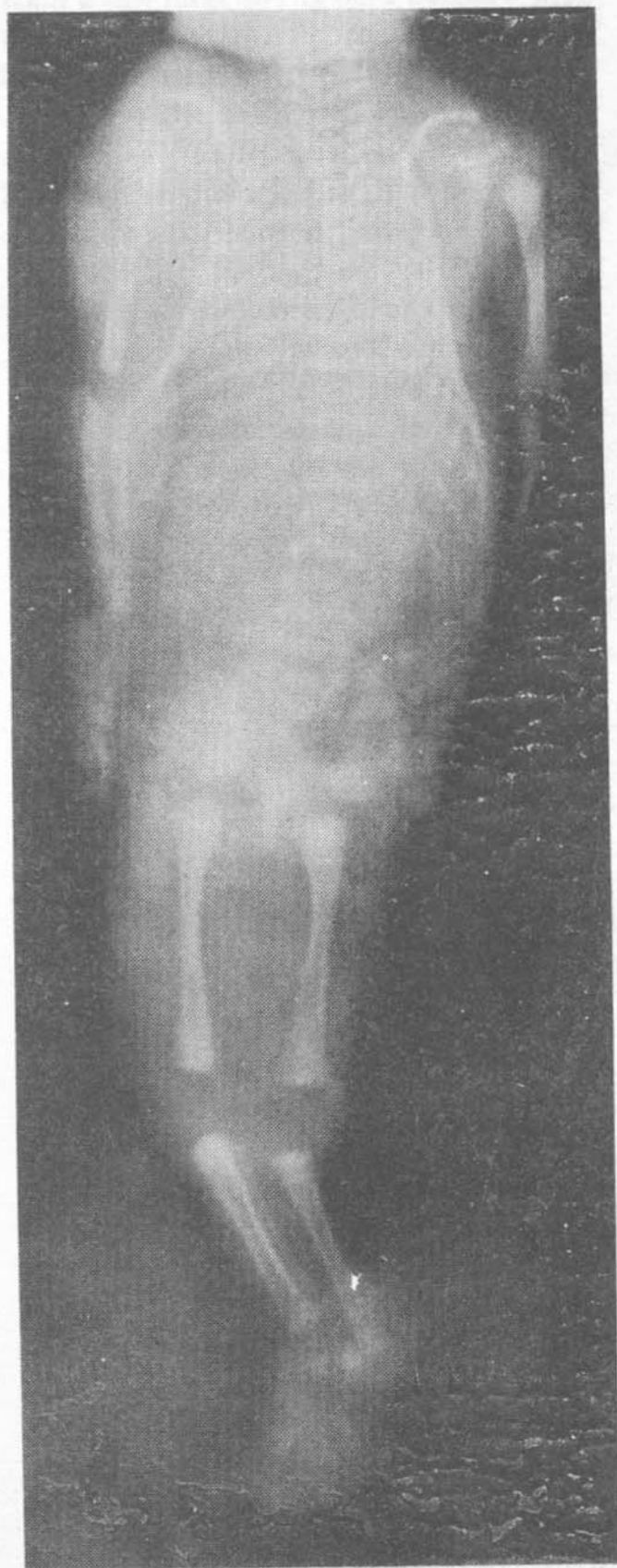
It has recently been shown that sirenomelia and its associated defects are produced by an alteration in early vascular development(8). Dissection of the abdominal vasculature in 11 cases of sirenomelia has demonstrated the presence of a single large artery arising from the aorta just below the diaphragm. This steal vessel derives from the vitelline artery complex, which is an early embryonic vascular network that supplies the yolk sac. This artery assumes the function of the umbilical arteries and diverts nutrients from the caudal end of the embryo distal to its site of origin. The abdominal aorta distal to the

---

*From the Nani Memorial Nursing Home, Quilon, and Department of Pediatrics, Kasturba Medical College, Manipal 576 119.*

*Reprint requests: Dr. Lalitha Krishnan, Department of Pediatrics, Kasturba Medical College, Manipal 576 119.*

*Received for publication November 24, 1990;  
Accepted April 5, 1991*



*Fig. Sirenomelia: showing soft tissue fusion of lower limbs, medial rotation of right fibula and single foot.*

origin of the major vessel is always subordinate and has no branches before it bifurcates into the iliac arteries. Consequently tissues dependent on nutrients supplied by this hypoplastic vascular system may be absent (e.g., kidneys), arrested at an incomplete stage of development (e.g., hindgut or genital tract) or aberrantly formed (e.g., lowerlimbs). Thus, as with other disruptive vascular defects, no two cases of sirenomelia are the same.

It is possible to demonstrate sirenomelia by ultrasound as early as 20 weeks of pregnancy(9). As it is lethal an attempt should be made to identify this condition in cases of IUGR and/or oligohydramnios at this stage.

#### REFERENCES

1. Jones KL. Smith's Recognizable Patterns of Human Malformation. 4th edn. Philadelphia, W.B. Saunders Company, 1988, p 574.
2. Pratap S, Nalini V, Rao RV, Rao PLNG. Sirenomelia: A case report. Asia-Oceania J Obstet Gynecol 1987, 13: 265-269.
3. Bhandari B, Tak SK, Mehta R. Sirenomelia with exomphalos major. J Indian Med Assoc 1982, 78: 157-160.
4. Bhandari B, Bhandari PC, Mathur A. Sirenomelia with exomphalos associated with absent hindgut. Indian Pediatr 1979, 16: 1045-1046.
5. Sharma DB, Ghosh S. Sirenomelia with exomphalos. Indian Pediatr 1975, 12: 612.
6. Puwar MB, Deshpande AS, Jawade SB. Sirenomelia: A case report. Asia Oceania J Obstet Gynecol 1985, 11: 199-202.
7. Saxena K, Malhotra J, Malhotra N, Naeem M. Mermaid fetus. A rare case.

Asia Oceania J Obstet Gynecol 1987, 13: 293-295.

8. Stevenson RE, Jones KL, Phelan MC *et al.* Vascular steal: The pathogenetic mechanism producing sirenomelia and associated defects of the viscera and soft tissues. *Pediatrics* 1986, 78: 451-457.
9. Leonidas JC, Berdon WE. The genitourinary tract. In: *Essentials of Caffey's Pediatric X-ray Diagnosis*. Eds Silverman FN, Kuhn JP, Chicago, Year Book Medical Publishers, 1990, p 1063.

## Familial Fibrous Dysplasia of the Jaws: Cherubism in Two Brothers

P. Mukherjee

S.K. Sinha Roy

P. Mukhopadhyay

Familial fibrous dysplasia (Cherubism) is a rare disease characterised by painless swelling of the jaws or cheeks, firm protuberant intraalveolar masses and missing or displaced teeth. This condition was first reported by Jones in 1933 in three Jewish siblings(1). It was termed 'Cherubism' because of the typical facial appearance in these children characterised by chubby

cheeks with upward projection of the eyeballs, due to growth arising from the maxilla. The disease has a strong familial predilection and probably occurs due to local disturbance in the embryogenesis.

This report illustrates cherubism diagnosed and treated surgically in two siblings.

### Case Report

Two brothers (PRP and DRP) (*Fig. 1*) aged 7 years and 4 years respectively presented with bilateral symmetrical swellings arising from the lower jaws. These swellings were painless, bony hard in consistency with no signs of inflammation. Dental examination revealed labially positioned mandibular canine and premolar teeth on both the sides which were out of occlusion, bulging into the buccal sulcus of the lower jaws on both sides from the canine to the 1st molar teeth. Maxillae and other bones of the body were unaffected.

Radiology of the lower jaws of both the cases revealed large well defined osteolytic areas within the body and part of the ramus of the mandible on both the sides. There was expansion of bone and thinning of the cortical margins more pronounced on the left side (PRP). A thin septae within the osteolytic lesions were also seen. The unerupted premolars were not well-developed and they were below the roots of the deciduous molars (DRP) (*Fig. 2*). A routine blood picture and urine examination were normal. Serum calcium, phosphorus and alkaline phosphatase levels were within normal limits.

The cases were planned to undergo an excision and curettage for histopathological confirmation and as a part of surgical management. The older child (PRP) was operated upon first on the right side of the lesion. After one week the younger

*From the Department of Pediatrics Surgery, Nilratan Sircar Medical College, Calcutta and Department of Anesthesiology, Institute of Post Graduate Medical Education and Research, Calcutta.*

*Reprint requests: Dr. Pradip Mukherjee, 13, Dixon Lane, Calcutta 700 014.*

*Received for publication March 26, 1990;*

*Accepted June 28, 1991*