

Use of the Pediatric Appendicitis Score in a Community Hospital

DONG YEON KIM, DONG HO SHIM AND KY YOUNG CHO

From the Department of Pediatrics, KEPCO Medical Center, Seoul, Republic of Korea

Correspondence to:

Dr. Ky Young Cho,

Department of Pediatrics,

KEPCO Medical Center, 308,

Uicheon-ro, Dobong-gu, Seoul,

Republic of Korea.

choky96@daum.net

Received: May 22, 2015;

Initial review: July 31, 2015;

Accepted: December 05, 2015.

Objective: To suggest the use of the Pediatric appendicitis score (PAS) for diagnosing acute pediatric appendicitis in a community hospital.

Methods: We retrospectively reviewed the data of 285 patients aged 3 to 17 years who underwent abdominal computed tomography (CT) for suspected acute appendicitis at a single community hospital. The PAS score was compared with the CT findings in the appendicitis ($n=86$) and non-appendicitis ($n=199$) group.

Results: The appendicitis group had a significantly higher PAS and more frequently positive CT findings for appendicitis than the non-appendicitis group ($P<0.01$). There were no significant differences in the diagnostic performance of the PAS and CT. Patients with a PAS of 1 to 3 could be discharged without further imaging study, those with a PAS of 4 to 6 might need to undergo further imaging study, and those with 7 to 10 PAS required surgical consultation with imaging study.

Conclusions: The application of this score could help in reducing the reliance on CT and in standardizing the clinical assessment in a community hospital.

Keywords: *Computed tomography, Evaluation, Management.*

Several clinical scoring systems have been developed to diagnose children with suspected appendicitis to avoid unnecessary computed tomography (CT) [2]. CT is increasingly being used as an initial evaluation of acute abdomen in children [3], though the risk of radiation exposure remains [4,5]. Among these scoring systems, the Pediatric Appendicitis Score (PAS) is a diagnostic tool that combines symptoms, physical examination, and laboratory results on a 10-point scale for children in whom acute appendicitis is suspected [6].

The primary objective of our study was to evaluate and compare the diagnostic value of the abdominal CT and the PAS for pediatric appendicitis. The second objective was to provide guidelines for imaging and treatment of pediatric patients in whom appendicitis was suspected in a community hospital, on the basis of the PAS.

METHODS

This retrospective study of patients who underwent abdominal CT for suspected acute appendicitis at the Emergency of the Pediatric and General Surgical Departments was performed in a single community hospital in Seoul, Korea between August 2013 and August 2014.

The following data were collected from records: patient's age, sex, weight, height, the time of examination, the onset of symptoms, each of the eight PAS items and radiologic findings. For patients who underwent a surgery, the pathology and surgical records were collected. CT findings were classified into five grades using a modified grading system [7]: Grade I, normal; Grade II, probably no appendicitis; Grade III, intermediate; Grade IV, probable appendicitis; and Grade V, absolutely appendicitis. We defined Grade I and II as negative findings, and Grade III and IV as positive findings specific for acute appendicitis on abdominal CT. The PAS score was calculated for each patient and was correlated to the final pathology reports and CT results by a pediatrician. Patients were divided into two groups: pathologically confirmed cases of acute appendicitis (AA group) and non-confirmed cases (non-AA group).

Accompanying Editorial: Pages 201-02.

Data were analyzed using SPSS, version 17.0 and MedCalc, version 12.0. Clinical and analytical variables of the two groups were compared using the chi-square test and Student's *t* test. The logistic regression analyses and the construction of Receiver operating characteristics (ROC) curves with optimal cutoff points were

performed. Statistical significance was assigned to *P* values <0.05.

RESULTS

A total of 285 patients (51.9% boys) aged 3 to 17 years [(mean (SD): 13.2 years (3.0)] were included of which 92 (32.3%) underwent surgery (6 patients (6.5%) had normal histology and included in the non-AA group). Thus, 86 patients (30.2%) were included in the AA-group and 199 patients (69.8%) were included in the non-AA group.

The AA group had a significantly higher PAS than the non-AA group (*P*<0.01) (**Table I**). The findings of appendicitis on abdominal CT were positive more frequently in the AA group than in the non-AA group (*P*<0.01) (**Table I**). The areas under the ROC curve (AUC) for PAS and CT was 0.89 and 0.94, respectively, and were not significantly different (**Fig. I**). The cutoff point of 7 or higher on the PAS would have yielded the 61 pathologically confirmed cases of appendicitis, among the 78 suspected patients, with a sensitivity of 70.9%, a specificity of 91.5%, a positive predictive value (PPV) of 78.2% and a negative predictive value (NPV) of 87.9%. The cutoff point of 3 or higher on the CT grade would have yielded the 73 pathologically confirmed cases of appendicitis among the 77 suspected patients, with a sensitivity of 89.5%, a specificity of 91.5%, a PPV of 94.8% and a NPV of 93.7%.

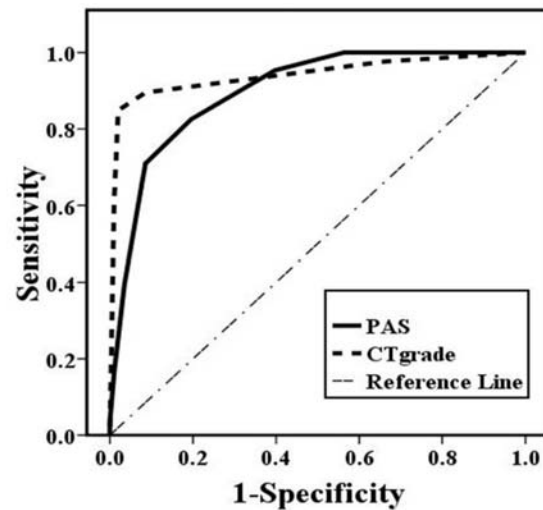
Anorexia, migration of pain to the right lower quadrant, cough tenderness, leukocytosis, and

TABLE I COMPARISON BETWEEN APPENDICITIS (AA) AND NON-APPENDICITIS GROUPS (NON-AA) (N=285)

	AA (n=86)	Non-AA (n=199)
Age (y)	13.3 (3.0)	13.2 (3.0)
#Male sex	59 (68.6)	89 (44.7)
*PAS	7.1 (1.5)	3.8 (2.0)
*CT (positive)	79 (91.9)	(8.1)
<i>Items of PAS</i>		
*Anorexia	30 (34.9)	24 (12.1)
Nausea/emesis	49 (57.0)	96 (48.2)
Fever	9 (10.5)	26 (13.1)
*Migration of pain	78 (90.7)	113 (56.8)
*Tenderness in RLQ	86 (100)	133 (66.8)
*Cough/percussion tenderness	68 (79.1)	52 (26.1)
*Leukocytosis	71 (82.6)	68 (34.2)
*Neutrophilia	64 (74.4)	67 (33.7)

Values are mean (SD) or n (%)

PAS: Pediatric appendicitis score; CT: abdominal computed tomography; RLQ: right lower quadrant. **P* < 0.001; #*P* = 0.001.



	AUC (95% confidence interval)	<i>P</i> value
PAS	0.89 (0.86-0.94)	<0.001
CT grade	0.94 (0.9-0.98)	<0.001
Comparison between PAS and CT grade		0.06

FIG. I Receiver operating characteristic curves for the Pediatric appendicitis score and abdominal computed tomography grade. Abbreviations: AUC, area under the receiver operating characteristics; PAS, pediatric appendicitis score; CT, abdominal computed tomography.

polymorphonuclear neutrophilia were most powerful predictive items of PAS for acute appendicitis in logistic regression (*P*<0.01) (**Table II**).

The frequencies of the appendicitis in patients with a PAS of 0-3, 4-6 and 7-10 were significantly increased (*P*<0.01) (**Table III**). No patients with a PAS of 3 or lower were diagnosed with acute appendicitis and their mean duration (SD) of surgical observation at hospital

TABLE II COMPARISON BETWEEN THE APPENDICITIS AND NON-APPENDICITIS GROUP*

Parameter	Odds Ratio	95% CI	<i>P</i> value
Anorexia	7.1	2.6-19.5	<0.001
Nausea/emesis	0.9	0.4-2.0	0.761
Fever	0.5	0.1-1.6	0.215
Migration of pain	3.9	1.2-12.3	0.022
Cough/percussion tenderness	6.7	3.0-14.7	<0.001
Leukocytosis	4.8	1.4-16.5	0.012
#Neutrophilia	4.0	1.2-13.7	0.027

RLQ, right lower quadrant; # >7.5×10⁹/L. *Logistic regression analysis.

TABLE III COMPARISON OF THE FREQUENCY OF APPENDICITIS IN PATIENTS WITH DIFFERENT PAS

PAS	0-3		4-6		7-10		P value
	AA	Non-AA	AA	Non-AA	AA	Non-AA	
No. (%)	0 (0)	87 (100)	25 (21.1)	95 (79)	61 (78.2)	17 (21.8)	<0.001*
CT grade, mean (SD)		0.7 (0.6)	2.9 (1.2)	0.9 (0.7)	3.5 (0.9)	1.1 (0.9)	<0.001

*Comparisons of AA vs Non-AA in patients by chi-square test and student T-test. PAS, pediatric appendicitis score; CT, abdominal computed tomography; AA, appendicitis group; Non-AA, non-appendicitis group.

was 2.3 (1.1) days (**Table III**). Acute appendicitis was confirmed by pathological findings in all cases with a PAS of 7 or higher who underwent surgery.

DISCUSSION

In this review of medical records at a community hospital, PAS was as valid as the abdominal CT for the diagnosis of pediatric appendicitis. Patients with scores of 1 to 3 could be discharged without additional abdominal CT whereas those with scores >7 needed to undergo surgical consultation and abdominal CT. For patients with scores of 4 to 6, a single score cannot accurately determine the diagnosis of appendicitis, because the mean CT grade in the AA group is significantly higher than in the non-AA group, despite the statistically significant lower frequencies of appendicitis ($P<0.01$). Therefore, patients with these scores might need to undergo the further imaging studies or evaluation with repeated PAS.

Abdominal CT has been reported to be a reliable diagnostic modality for acute appendicitis [1,8]. In agreement with the previous studies, we showed that the cutoff point of 3 for the CT grade yielded a high sensitivity and specificity for diagnosing the acute appendicitis. Some studies have suggested guidelines for the diagnosis and treatment of acute appendicitis by using the PAS [9]. Samuel [6] reported that the PAS of 6 or greater was indicative of a high probability of appendicitis. Goldman, *et al.* [10] reported that a score of 7 or greater is valid for the diagnosis of appendicitis and a score of 2 or under is valid for the exclusion of appendicitis. We suggest the guidelines for assessing an acute abdomen according to the cutoff points of the PAS.

To our knowledge, this is the first study to evaluate the diagnostic value of the PAS by comparing with the abdominal CT for pediatric appendicitis. The sensitivity (70.9%) of the PAS at the cutoff point of 7 was lower than the sensitivity (89.5%) of the abdominal CT at the cutoff point of 3 with the same specificity (91.5%). Comparing this result with other studies reveals that the PAS provides similar sensitivity and higher specificity than the ultrasonography (sensitivity 71.2%, specificity 83.3%)

for acute appendicitis [11]. Although the PAS alone is not likely to change the clinical decision in acute pediatric appendicitis, this score could be considered as an additional diagnostic tool for replacing the initial evaluation with the abdominal CT and for identifying the patients with a low risk of appendicitis in a community hospital where pediatric radiologist or pediatric surgeon may not be always available.

A repeat clinical examination after four hours of adequate intravenous fluid hydration using the PAS has been proposed, if the diagnosis of appendicitis is not clear [6]. A limitation of our study is that we did not perform a repeat clinical examination using the PAS. Another limitation is the nature of the retrospective study design itself. To clarify the diagnostic value of the PAS, a prospective multicenter study, with a large number of patients and recurrent clinical examination using the PAS will be needed.

In conclusion, the PAS was as useful and relatively accurate as the abdominal CT for assessing an acute abdomen and diagnosing acute pediatric appendicitis. PAS could be an additional diagnostic modality to reduce the reliance on abdominal CT and to standardize the clinical assessment in a community hospital.

Contributors: DYK: conception or design of the work, acquisition, analysis, interpretation of data for the work; DHS: reviewed the literature and contributed towards drafting of the manuscript; KYC: conception of the work, drafting the work or revising it critically for important intellectual content. All authors approved the final version of the manuscript.

Funding: None; *Competing interests:* None stated.

REFERENCES

- Schneider C, Kharbanda A, Bachur R. Evaluating appendicitis scoring systems using a prospective pediatric cohort. *Ann Emerg Med.* 2007;49:778-84.
- Doria AS. Optimizing the role of imaging in appendicitis. *Pediatr Radiol.* 2009;39 Suppl 2:S144-8.
- Larson DB, Johnson LW, Schnell BM, Goske MJ, Salisbury SR, Forman HP. Rising use of CT in child visits to the emergency department in the United States, 1995-2008. *Radiology.* 2011;259:793-801.

WHAT THIS STUDY ADDS?

- The Pediatric Appendicitis Score could be as valid as the CT for diagnosing pediatric appendicitis in a community hospital.

- Pearce MS, Salotti JA, Little MP, McHugh K, Lee C, Kim KP, et al. Radiation exposure from CT scans in childhood and subsequent risk of leukaemia and brain tumours: A retrospective cohort study. *Lancet*. 2012;380:499-505.
- Saito JM, Yan Y, Evashwick TW, Warner BW, Tarr PI. Use and accuracy of diagnostic imaging by hospital type in pediatric appendicitis. *Pediatrics*. 2013;131:e37-44.
- Samuel M. Pediatric appendicitis score. *J Ped Surg*. 2002;37:877-81.
- Raptopoulos V, Katsou G, Rosen MP, Siewert B, Goldberg SN, Kruskal JB. Acute appendicitis: Effect of increased use of CT on selecting patients earlier. *Radiology*. 2003;226:521-6.
- van Randen A, Bipat S, Zwinderman AH, Ubbink DT, Stoker J, Boermeester MA. Acute appendicitis: Meta-analysis of diagnostic performance of CT and graded compression US related to prevalence of disease. *Radiology*. 2008;249:97-106.
- Ebell MH, Shinholser J. What are the most clinically useful cutoffs for the Alvarado and Pediatric Appendicitis Scores? A systematic review. *Ann Emerg Med*. 2014;64:365-72.
- Goldman RD, Carter S, Stephens D, Antoon R, Mounstephen W, Langer JC. Prospective validation of the pediatric appendicitis score. *J Pediatr*. 2008;153:278-82.
- Nasiri S, Mohebbi F, Sodagari N, Hedayat A. Diagnostic values of ultrasound and the Modified Alvarado Scoring System in acute appendicitis. *Int J Emerg Med*. 2012;5:26.