

Spigelian Hernia

Spigelian hernias are rare and most patients are diagnosed between 40 and 70 years of age(1). Only twenty cases in the pediatric age group are reported(2). We report a case of vague abdominal pain with an occult, non palpable Spigelian hernia in whom the diagnosis was confirmed by ultrasonographic examination of the abdominal wall.

A 12-year-old boy presented with vague pain in left lower abdomen for the last one year. He had been treated with several courses of antiamebic, antihelminthic and antibiotic drugs without satisfactory relief. The pain was intermittent and localized to the abdominal wall. It was aggravated by manoeuvres that increased intra-abdominal pressure and was relieved by rest. The physical examination was normal except for a distinct tender point over the left Spigelian fascia when the abdominal muscles were tensed (Fig.). A small defect in the Spigelian fascia at this point could be palpated without any palpable mass or a sac. Laboratory investigations, plain radiographs of the abdomen, barium meal and enema examinations and intravenous ultrasonography were normal. An ultrasound examination of the abdominal cavity was normal. However, on abdominal wall ultrasonography, in supine position with abdominal muscles relaxed, a hernial open-

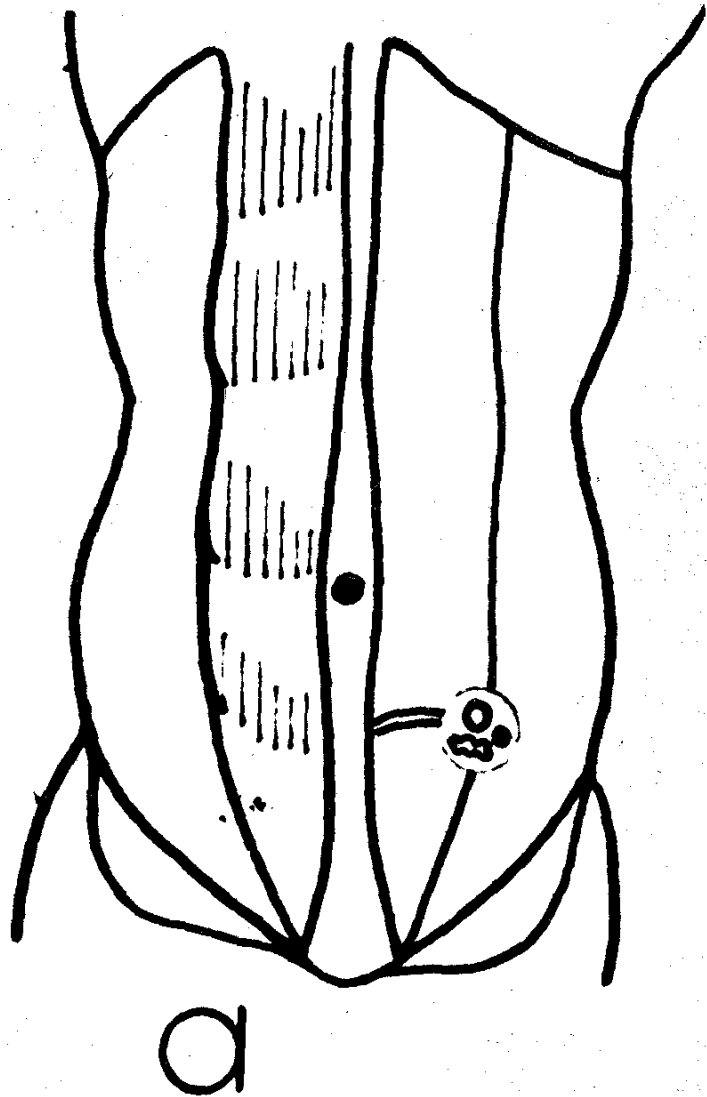


Fig. Diagram showing the location of hernia having sharply defined edges and small hernial orifice containing preperitoneal fat surrounding the sac and a neurovascular bundle.

ing in the Spigelian fascia was seen as a discontinuity in the echoline from the aponeurosis.

Examination under anesthesia showed an ill defined mass within the defect. At exploration, via a transverse skin crease cutaneous incision centered over the ten-

der area and a grid iron abdominal wall incision, the Spigelian hernia was located after splitting the external aponeurosis. The hernial orifice was small, the edges were well defined and rigid. The contents included preperitoneal fat surrounding a peritoneal sac and a neurovascular bundle. The hernial orifices were enlarged, the sac was opened and abdominal viscera inspected and palpated. The sac was excised and hernia repaired using nonabsorbable monofilament nylon sutures. The post-operative period was uneventful. Following discharge at follow up 1 year later, he was asymptomatic, free of pain and there was no recurrence of the hernia.

Protrusion of a preperitoneal fat, peritoneal sac or an organ from its normal position through a defect in the Spigelian fascia is referred to as a Spigelian hernia. Most such lesions are acquired, small, non-palpable and located below the umbilicus between the parietes. The hernial orifice is usually oval or round, and the edges are well defined and rigid. Neurovascular bundle from the intercostal vessels and nerves may have natural openings in Spigelian fascia created by their anterior cutaneous branches. Enlargement of such neurovascular opening as a predisposing factor has been reported earlier and finding of neurovascular bundle in the hernial orifice of our patient also supports this theory(2).

It is generally difficult to clinically diagnose Spigelian hernia because of non-specific symptoms and the often intramural location of the hernia beneath an intact external oblique aponeurosis(3). Distinct tenderness over the hernial orifice is not pathognomonic of Spigelian hernia but offers a useful method for screening. Cross table ultrasonographic examination or computerized tomographic scanning of the abdominal wall may allow early

diagnosis(4). The results of surgical repair are excellent and the risk of recurrence is low(5).

**S.G. Mehta,
R.V. Patel,
N. Agravat,
S.N. Sheikh,
P.S. Trivedi,**

*Departments of Pediatrics and Surgery,
M.P. Shah Medical College and
Irwin Group of Hospitals,
Jamnagar.*

REFERENCES

1. Das D, Shukla HS. Spigelian hernia in differential diagnosis of right iliac fossa pain. *Indian J Surg* 1988, 50: 380-382.
2. Spangen L. Spigelian hernia. *In: Hernia*, 3rd edn. Eds Nyhus LM, Condon RE. Philadelphia, J.B. Lippincott, 1989, pp 369-380.
3. Spangen L. Spigelian hernia. *Surg Clin N Am* 1984, 64: 351-356.
4. Nelson RL, Renigers SA, Nyhusm LM, *et al.* Ultrasonography of the abdominal wall in the diagnosis of Spigelian hernia. *Am Surg* 1980, 46: 373-376.
5. Ponka JL. Spigelian hernia. *In: Hernias of the Abdominal Wall*, 1st edn. Ed Ponka JL. Philadelphia, WB Saunders, 1980, pp 478-496.

Neonatal Branding—Towards Branding Eradication

It was interesting to read the article on neonatal branding by Mohapatra(1). We agree with the author that this is a hazardous practice and steps should be taken at all levels to discourage this. In our hospital we have started maintaining an accurate record of branding cases in a 'Branding