

Vertebral Hemangioma with Spinal Cord Compression: The Role of Pre-operative Embolisation

N. Khandelwal
N. Malik
D.S.G. Rao
V.K. Kak
S. Suri

Vertebral hemangiomas (VH) are slow growing benign vascular tumors found in 11% of spines at autopsy(1). Despite its common occurrence, spinal cord compression due to VH is extremely rare(2). A case of VH with cord compression is described to illustrate the role of CT scan, arteriography and pre-operative embolisation in their diagnosis and management.

Case Report

A girl aged 12 years presented with back pain and progressive weakness of both lower limbs for 25 days. There was no history of trauma or bladder dysfunction. On examination, she had spastic paraplegia with 0/5 power. Touch and pain sensations were impaired below T-12 level. Plain radiographs of the dorsal spine revealed coarse vertical striations at D-9 with intact

cortical contour. Iohexol myelogram showed a complete extradural block at D-9-D-10 space. Plain CT scan revealed involvement of whole of the vertebral body and the pedicles with expanded thin cortical outline, irregular trabeculations and paravertebral soft tissue mass (Fig. 1).

Selective arteriogram showed dilatation of arterioles and intense contrast blush involving the body and pedicles of the vertebra with extension into the spinal canal (Fig. 2). The lesion was embolised with gelfoam. Postembolisation arteriogram showed almost total disappearance of the tumor blush. The anterior spinal artery was clearly seen which was originating at the T-9 level (Fig. 3). Twenty four hours later laminectomy of D-8 and D-9 was performed. The laminae of D-9 were expanded and contained large vascular spaces containing old clotted blood. A generous decompression was achieved with minimal blood loss. A small bunch of

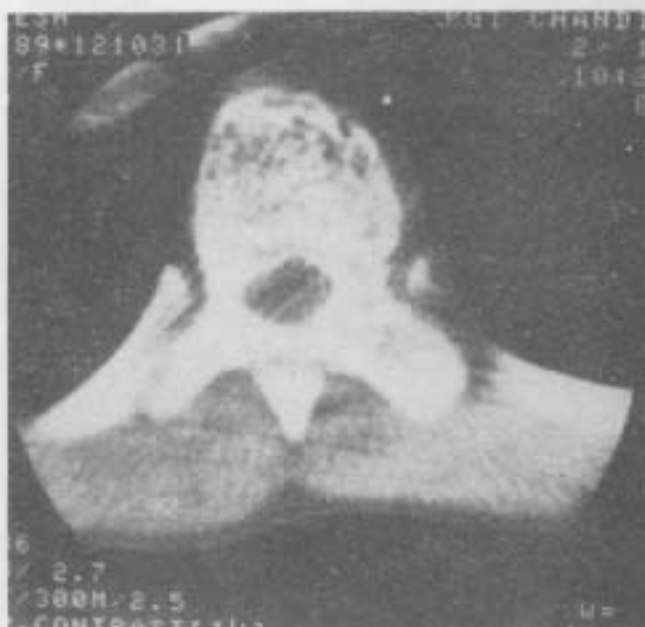

Fig. 1. CT scan at T-9 level shows coarse trabeculae involving almost entire vertebral body with thinning of cortex. Note involvement of pedicles.

From the Departments of Radiodiagnosis and Neurosurgery, Postgraduate Institute of Medical Education and Research, Chandigarh 160 012.

Reprint requests: Dr. N. Khandelwal, Assistant Professor, Department of Radioagnosis, P.G.I.M.E.R., Chandigarh 160 012.

Received for publication: September 6, 1991;

Accepted: December 10, 1991

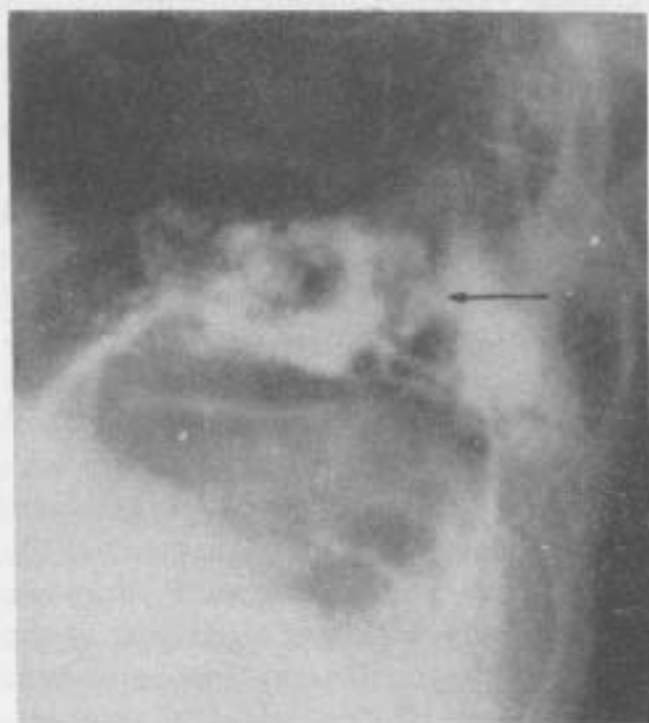


Fig. 2. Selective arteriogram shows intense blush involving vertebral body with extension into spinal canal (arrow).

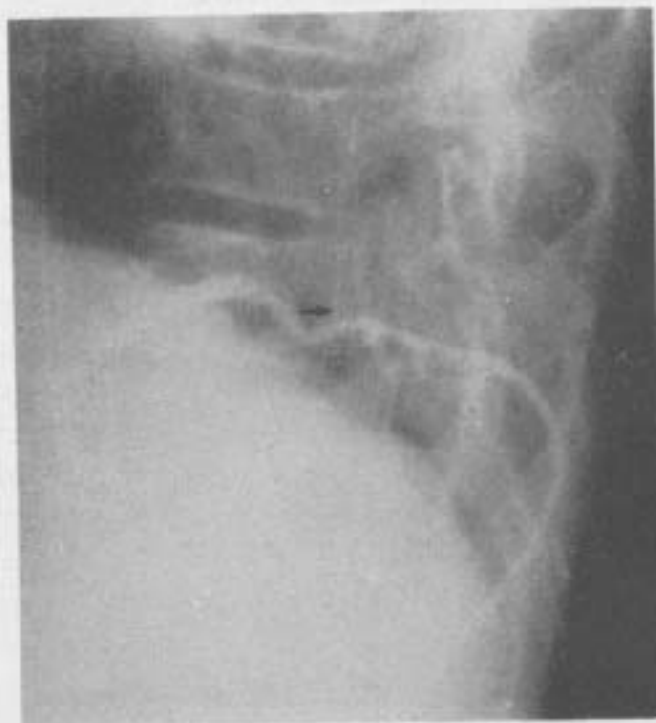

Fig. 3. Post embolisation arteriogram shows complete disappearance of tumor blush. Note well-visualized anterior spinal artery (arrow).

abnormal epidural vessels was also excised. Her postoperative course was uneventful.

Histological examination of excised tissue confirmed it to be a vertebral hemangioma. She received postoperative irradiation with a total dose of 2500 c Gy in 10 fractions. She showed a rapid neurological improvement and had fully recovered in 6 months' time.

Discussion

Vertebral hemangiomas (VH) are subdivided into three categories according to clinical criteria: (a) asymptomatic VH (AVH), (b) Compressive VH (CVH), and (c) symptomatic VH (SVH)(3). CVH can occur at any age with a peak frequency in young adults and slight female predominance(1). It commonly occurs in the dorsal region between D-3 to D-9 levels(4). The diagnosis of VH is essentially based on radiological findings. Plain X-rays show vertically arranged coarse trabeculae, expanded cortex or a paravertebral soft tissue mass. CT scan is not only diagnostic but also predicts the compressive form of VH. CVH shows additional features of active (poorly defined expanded cortex, irregular trabeculae) and extensive vascular tumor (involvement of entire vertebral body and neural arch with soft tissue extension) in the CT scan(3). Myelography established the site and extent of extradural block. MRI findings are also characteristic. The increased signal on T₁WI and T₂WI coupled with mottled appearance of vertebral bodies are specific for hemangiomas(3). Selective arteriography adds little to the diagnosis but is an obligatory procedure in CVH(2). The arteriographic features include dilatation of arterioles, blood pools and lack of early venous drainage. There is intense opacification of the vertebral body and surrounding paravertebral soft tissue. The cause of

spinal cord compression is mostly due to extra-dural extension of the angioma rather than bony expansion(5). Embolisation of feeding arteries, avoiding the anterior spinal artery supplying the cord, helps in reducing the intra operative blood loss and facilitates surgery(6).

The management of CVH is still controversial. Embolisation alone is recommended as the only and most definitive therapy by some authors(6,7). Decompressive laminectomy alone or radiotherapy following laminectomy has not been reported as frequently in recent literature(8). In order to prevent delayed collapse of vertebral body, stabilisation can be achieved by preoperative retrograde embolisation with methyl methacrylate or low dose radiotherapy, thus obviating major stabilisation procedures using bone or metal rods(8).

REFERENCES

1. Schmorl G, Junghanus H. The Human Spine in Health and Disease. New York, Grune & Stratton, 1971.
2. Mohan V, Gupta SK, Tuli SM, Sanyal B. Symptomatic vertebral hemangiomas. Clin Radiol 1980, 31: 575-579.
3. Laredo JD, Reizine D, Bard M, Merland JJ. Vertebral hemangiomas: Radiologic evaluation. Radiology 1986, 161: 183-189.
4. Gasten A, Nguyen JP, Djindjian M. Vertebral hemangioma: CT and arteriographic features in three cases. Neuroradiology 1985, 12: 21-23.
5. Chittipantulu G, Dinakar I, Ramachandrarao S, Venkataramana G, Somayajulu MVRJ, Satyanarayana VV. Spinal cord compression due to hemangioma of vertebra (Report of two cases). J Assoc Phys India 1986, 34: 663-664.
6. Gross CE, Hedge Ch J, Binet EF, Kricheff II. Relief of spinal block during

embolisation of a vertebral body hemangioma. J Neurosurg 1976, 45: 327-330.

7. Nguyen JP, Djindjian M, Gaston A, *et al.* Vertebral hemangiomas presenting with neurologic symptoms. Surg Neurol 1987, 27: 391-397.
8. Nicola N, Lins E. Vertebral hemangioma: Retrograde embolization — stabilisation with methyl methacrylate. Surg Neurol 1987, 27: 481-486.

Impact of Universal Immunization Programme on the Incidence of Tetanus Neonatorum

P.L. Joshi
M. Bhattacharya
R.C. Arya
B. Raj
D. Walia

Disease surveillance data is required to streamline immunization activities and direct measures to areas where they are needed. We report the impact of Universal Immunization Programme (UIP) on the incidence of neonatal tetanus in a rural area of Allahabad.

Material and Methods

This study was carried out in Jasra

From the Department of Social and Preventive Medicine, M.L.N. Medical College, Allahabad.

Reprint requests: Dr. M. Bhattacharya, Associate Professor, Department of Social and Preventive Medicine, M.L.N. Medical College, Allahabad 211 001.

Received for publication: June 24, 1991;

Accepted: January 2, 1992